



## Open conversion for refractory type II endoleaks. Is it the best way?

\*Corresponding Author: **Jon Peckham**

Email: [sa128762@atsu.edu](mailto:sa128762@atsu.edu)

### Abstract

**Introduction:** Type II endoleaks occur frequently following Endovascular Aortic Repair (EVAR), which, in most cases, does not require any treatment. However, managing persistent endoleaks that enlarge the aneurysm sac can be challenging and may require less invasive measures (endovascular interventions). Open Conversions (OCs) are well described in the literature but are invasive and negate the advantages of EVAR.

**Case presentation:** A 70-year-old male patient, with multiple but stable medical comorbidities, had CT evidence of an expanding aneurysm over several years >7.0 cm without a clear source of endoleak. Transarterial embolization failed, which is common. Newer techniques, such as transcaval or translumbar embolizations, have shown promise; however, experience and specialized equipment are less widespread among vascular surgeons. We eventually shifted to an OC and identified, ligated, or oversewed multiple vessels feeding into the aneurysm sac. The patient recovered without major complications but underwent ventral hernia repair a year after the procedure. Follow-up imaging for the first two years has shown sac size regression and stability, and this approach has been practical.

**Discussion/Conclusion:** He may have benefited from newer techniques, but we could not offer him in our private practice or community. Some studies have shown that contemporary approaches are superior to conventional ones. This case aimed to spark conversation among the vascular surgical community regarding whether more ubiquitous training for these techniques is needed.

### Introduction

Endovascular Aneurysm Repair (EVAR) has been the modality of choice for elective Abdominal Aortic Aneurysms (AAA) for over 30 years [1] owing to its shorter operating length, decreased length of stay, invasive nature compared to Open Surgical Repair (OSR), physician and patient preference [2-7], and immediate morbidity and mortality benefits [3]. However, Type

**Jon Peckham\***; **Stephen Smith**

Division of Hematology and Oncology, University of Washington, Seattle, WA, USA.

**Received:** Apr 24, 2024

**Accepted:** May 17, 2024

**Published Online:** May 24, 2024

**Journal:** Annals of Surgical Case Reports & Images

**Online edition:** <https://annsri.org>

**Copyright:** © **Peckham J** (2024). This Article is distributed under the terms of Creative Commons Attribution 4.0 International License.

**Cite this article:** Peckham J, Smith S. Open conversion for refractory type II endoleaks. Is it the best way?. Ann Surg Case Rep Images. 2024; 1(3): 1028.

**Keywords:** Abdominal aortic aneurysm; Type II endoleak; Transcaval; Translumbar embolization.

II Endoleaks (T2Es), defined as retrograde collateral blood flow into the aneurysm sac from the lumbar or Inferior Mesenteric Artery (IMA), are a common complication, occurring in 16%-50% of EVARs [2,8]. The course of T2Es varies significantly, and many resolve spontaneously. Others persist but do not cause significant sac enlargement, whereas others continue to grow with or without intervention. While many retrospective studies have been conducted in the last 30 years in larger institu-

tions and academic centers in the United States and Europe, the consensus on treating persistent T2Es with increasing sac size varies, especially among community-based vascular surgeons. However, there is now a consensus regarding the treatment of all type II endoleaks when sac enlargement exceeds 5 mm in a 6-month interval [4]. It is common to attempt to resolve them with minimally invasive measures initially and to reserve surgical conversion in refractory cases when the aneurysm grows too large, becomes symptomatic, and there is an unacceptable risk of rupture. Newer techniques, such as transcaval or translumbar embolization, have shown promising results. However, standardized training in fellowship programs has been developing slowly. Herein, we present a case in which standard transarterial embolization failed. Without other techniques at our disposal, we provided the patient with the option of another attempt at the transarterial approach or open conversion. He opted for the latter but may have benefited from a newer endovascular approach.

### Case presentation

A 70-year-old male with several comorbidities (stable essential hypertension, dyslipidemia on chronic statin therapy, CKD III, GERD, COPD with pulmonary blebs, and a history of spontaneous pneumothorax) presented to the vascular clinic for a routine follow-up visit for an enlarging AAA despite a previous EVAR. He initially underwent EVAR with bilateral accessory renal artery embolizations for a 5.8 cm AAA on 12/01/2016. Accessory renal embolization was performed due to the large size (>4 mm) of the arteries. A small, delayed type II endoleak was observed and presumed to be retrograde flow from the lumbar arteries. The endoleak continued to be present on subsequent CT angiography over the next two years, but with a minimal increase in sac size (6.0 cm). Although the patient remained asymptomatic, there was sufficient concern he was still at an unsatisfactory risk of sac rupture, and a decision was made to perform direct angiography and coil embolization of the lumbar arteries and aneurysm sac. However, these treatments are not always curative in nature. The patient was monitored bi-annually with US and non-contrast CT because of concerns regarding contrast nephropathy. There continued to be progressive growth of the aneurysm sac on this imaging until it reached 7.0 cm in April 2021 (1.2 cm change over 4.5 years) and was confirmed on CTA, where there appeared to be a small endoleak from the IMA. At this point, the patient was given the option of an angiogram with coil embolization of the IMA vs. open exploration of the AAA sac with ligation of the bleeding source and possible graft explantation, and chose the latter. Other approaches were not used in our toolkit and were not offered. Surgery was performed shortly after using the transperitoneal approach because of the surgeon's preference without a significant issue. The aorta and iliac vessels were dissected, and the loops were placed in preparation for sacotomy. However, there was no pulsation of the aneurysm; therefore, the aorta was not clamped before the incision into the sac. After a significant amount of thrombus was removed, vigorous bleeding was noted from the IMA and the left accessory renal artery, and each was ligated with a 2-0 silk oversewn suture.

Additionally, bleeding from the lumbar artery was observed, although to a much lesser degree, it was still oversewn. No further bleeding was noted prior to sac closure, and the endograft did not appear to have any structural or functional issues. Hemostatic agents were placed, and the sac was closed watertight with a Prolene suture in a running-locked fashion.

The patient did well after the surgery and was discharged on POD 5. He developed a ventral hernia that required a mesh one year after the procedure. He has complied with follow-up and had a post-op CTA at four months, which showed sac regression to 6.0 cm and no endoleak, and most recently, an abdominal US (8/2023) with a sac size down to 5.3 cm again with no sonographic evidence of further endoleak.

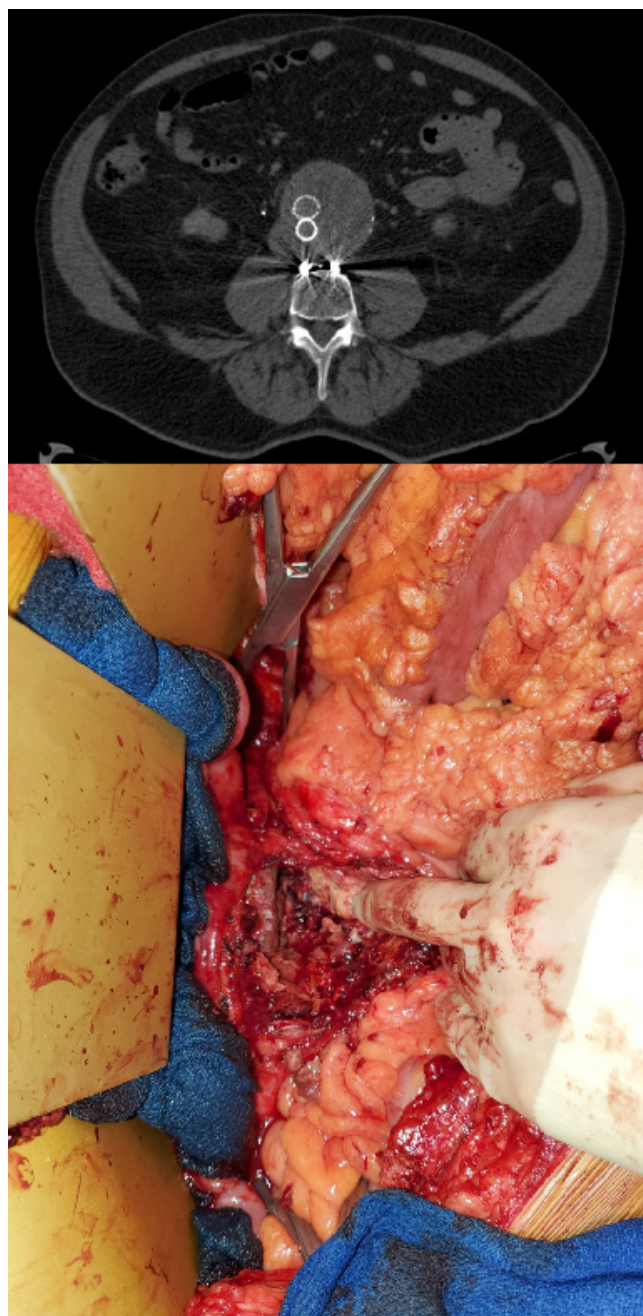


Figure 1: Clinical image.

### Discussion

T2Es are an unavoidable problem after EVAR. Many patients do not require interventions; however, this is not always the case. However, consensus on the treatment of persistent leaks with an enlarged aneurysm sac remains unclear. Furthermore, newer minimally invasive techniques, such as the transcaval or translumbar approaches, have shown promising results in small case studies and systematic reviews but are less impressive in others [9-16].

In our patient, transarterial embolization was attempted but ultimately failed, and we did not initially push for other

interventions. However, our patient became concerned with the aneurysm's increasing size to approximately 1 cm over two years after embolization. The patient was given the option of another transarterial embolization attempt or open conversion, which he preferred to undergo. In part, his decision was made because he wanted a procedure that he was assured would be definitive and had become tired of the imaging and surveillance processes. Other procedures, such as the transcaval and translumbar approaches, may have been better follow-up approaches because of their less invasive nature and high success rates [16-18]. However, anatomical considerations, specialized equipment, and training in these techniques are needed and are reserved for academic or larger institutions. The industry has begun to offer specialized courses to learn these procedures but at the physician's time and expense. If these treatments continue to be useful in managing T2Es, the vascular surgical community should emphasize exposure and instruction earlier in their training.

Although our patient has performed well with his treatment, our eventual open conversion negates the advantages of EVAR. While there is no clear consensus on the modality of choice in these situations, much of the literature suggests that attempting at least one transarterial intervention before considering others is prudent [19,20]. If this fails, which is not uncommon, safer, and minimally invasive (endovascular) options with adequate success rates would benefit vascular surgeons.

### Conclusion

Given the current technology available, T2Es that require intervention due to an enlarged sac size will continue to be an issue, given the frequency of EVAR. Many techniques are available and well described in the literature, with newer approaches such as transcaval and translumbar, as viable alternatives to transarterial or open repair. Although OC, as shown in our case, remains reliable and definitive, effective endovascular solutions are the preferred approach under many circumstances. However, more structured training and experience are needed during fellowships and for practicing vascular surgeons.

### Declarations

**Data access statement:** Data supporting this study are included in the article and/or supporting materials.

**Funding statement:** No funding was received for this study.

**Research:** This work was conducted under the supervision of Stephen Smith MD as a case study under no formal organization.

**Ethical compliance:** All procedures performed in this study involving human participants were in accordance with the ethical standards of the institutional and/or national research committee and the 1964 Helsinki Declaration and its later amendments or comparable ethical standards.

**Conflict of interest:** The authors declare that they have no affiliations with or involvement in any organization or entity with any financial interests in the subject matter or materials discussed in this manuscript.

### References

1. Carpenter JP, Baum RA, Barker CF, Golden MA, Mitchell ME, et al. Impact of exclusion criteria on patient selection for endovascular abdominal aortic aneurysm repair. *J. Vasc. Surg.* 2001; 34:

1050-1054.

2. Bryce Y, Schiro B, Cooper K, Ganguli S, Khayat M, et al. Type II endoleaks: Diagnosis and treatment algorithm. *Cardio-vasc Diagn Ther.* 2018; 8(Suppl 1): S131-S137. doi: 10.21037/cdt.2017.08.06.
3. Malas M, Arhuidese I, Qazi U, et al. Perioperative mortality following repair of abdominal aortic aneurysms: Application of a randomized clinical trial to real-world practice using a validated nationwide data set. *JAMA Surg* 2014;149:1260-5.
4. Moll FL, Powell JT, Fraedrich G, et al. Management of abdominal aortic aneurysms clinical practice guidelines of the European Society for Vascular Surgery. *Eur J Vasc Endovasc Surg.* 2011; 41(suppl 1): S1-S58. doi: 10.1016/j.ejvs.2010.09.011.
5. Columbo J, Martinez-Cambor P, O'Malley A, Suckow B, Hoel A, et al. Long-term Reintervention after Endovascular Abdominal Aortic Aneurysm Repair. *Annals of Surgery.* 2021; 274 (1): 179-185. doi: 10.1097/SLA.0000000000003446.
6. Reise JA, Sheldon H, Earnshaw J, Naylor AR, Dick F, et al. Patient Preference for Surgical Method of Abdominal Aortic Aneurysm Repair: Postal Survey. *Eur. J. Vasc. Endovasc. Surg.* 2010; 39: 55-61.
7. James McAndrew Jones BA, Yiyuan David Hu BA, Mark Anthony Eid MD, Catherine J, Sensenig BA, et al. Short-Term Concerns Primarily Determine Patient Preference for Abdominal Aortic Aneurysm Repair. *Journal of Surgical Research.* 2022; 269: 119-128.
8. D A Sidloff, PW Stather, E Choke, M J Bown, R D Sayers. Type II endoleak after endovascular aneurysm repair. *British Journal of Surgery.* 2013; 100: 1262-1270.
9. Rae S Rokosh, Winona W Wu A, Ronald L Dalman, Elliot L Chaikof. Society for Vascular Surgery implementation of clinical practice guidelines for patients with an abdominal aortic aneurysm: Endoleak management.
10. M Ferrari SG, Sardella R, Berchiolli D, Adami C, Vignali V, et al. Surgical Treatment of Persistent Type 2 Endoleaks, with Increase of the Aneurysm Sac: Indications and Technical Notes. *Eur J Vasc Endovasc Surg.* 2005; 29.
11. Joy Walker, Lue-Yen Tucke, Philip Goodney, Leah Candell, Hong Hua, et al. Type II endoleak with or without intervention after endovascular aortic aneurysm repair does not change aneurysm-related outcomes despite sac growth. *J Vasc Surg.* 2015; 62: 551-61.
12. Sana Mulay, Anna CM, Geraedts Mark, JW Koelemay, Ron Balm. ODYSSEUS study group. Type 2 Endoleak With or Without Intervention and Survival after Endovascular Aneurysm Repair. *Eur J Vasc Endovasc Surg.* 2021; 61: 779e786.
13. DA Sidloff, PW Stather, E Choke, MJ Bown, RD Sayers. Type II endoleak after endovascular aneurysm repair. *British Journal of Surgery.* 2013; 100: 1262-1270.
14. Nicola Mangialardi, Sonia Ronchey, Matteo Orrico, Eugenia Serrao, Vittorio Alberti, et al. Surgical conversion with graft salvage as a definitive treatment for persistent type II endoleak causing sac enlargement. *J Vasc Surg.* 2015; 62: 1437-41.
15. Julien Dié Loucou, Lucie Salomon du Mont, Aline Jazayeri, Anne Sophie Mariet, Mélanie eboffe, et al. Evaluation of the Effectiveness of Endovascular Treatment of Type 2 Endoleaks. *Annals of Vascular Surgery.* 2023; 93: 9-17.
16. Giancarlo Mansueto, Daniela Cenzi, Mirko DOnofrio, Enrico Petrella, Andrew A. Gumbs, Roberto Pozzi Mucelli. Treatment of Type II Endoleaks after Endovascular Repair of Abdominal Aor-

- 
- tic Aneurysms: Transcaval Approach. *Cardiovasc Intervent Radiol.* 2005; 28: 641-645.
17. Terhi Nevala Æ Fausto Biancari Æ Hannu Manninen Æ Pekka-Sakari Aho Æ Pekka Matsi Æ Kimmo Ma"kinen Æ Wolf-Dieter Roth Æ Kari Ylo"nen Æ Mauri Lepa"ntalo Æ Jukka Pera"la.
18. Caroline G, Burley Mark H Kumar, Waseem A Bhatti, Christina Boyd, Clifford M, et al. Transcaval embolization is the preferred approach. *J Vasc Surg.* 2019; 69: 1309-13.
19. Petroula Nana, Konstantinos Spanos, Franziska Heidemann, Giuseppe Panuccio, George Kouvelos, et al. Systematic review on transcaval embolization for type II endoleak after endovascular aortic aneurysm repair. *Journal of Vascular Surgery.* 2022; 76(1): 282-291.
20. Trans lumbar Embolization of Type II Endoleaks. 12 Years of Experience at a Regional Vascular Centre William Rhodri Thomas, Salil Karkhanis, Jonathan Hopkins, and Martin Duddy *Vascular and Endovascular Surgery.* 2020; 54(5): 389-394.
21. George A Antoniou, Stavros A, Antoniou, Francesco Torella. Editor's Choice - Endovascular vs. Open Repair for Abdominal Aortic Aneurysm: Systematic Review and Meta-analysis of Updated Peri-operative and Long-Term Data of Randomised Controlled Trials, *European Journal of Vascular and Endovascular Surgery.* 2020; 59(3): 385-397.
22. The Lancet, Open versus endovascular repair of aortic aneurysms, *The Lancet.* 2020; 95(10230): 1090.